

# Proximal Humeral Nonunions Treated With Fixed-Angle Locked Plating and an Intramedullary Strut Allograft

Brian L. Badman, MD,\* Mark Mighell, MD,\* Steven P. Kalandiak, MD,† and Mark Prasarn, MD‡

**Objective:** To determine if the use of a fixed-angle locked plate plus an intramedullary allograft in the treatment of proximal humeral nonunions resulted in improved union.

**Design:** Retrospective clinical analysis of patients' medical charts and radiographs.

**Setting:** Clinical practice of senior authors.

**Patients/Participants:** Eighteen patients who presented to the senior authors' clinic between 2001 and 2007 with clinical and radiographic evidence of symptomatic proximal humeral nonunions that were treated with the described method were included for analysis. Patients with severe humeral head bone loss, avascular necrosis, evidence of arthrosis, and less than 12-month clinical follow-up were excluded.

**Intervention:** All patients with a symptomatic viable nonunion of the proximal humerus were treated with a fixed-angle locked plate and an intramedullary cortical allograft.

**Main Outcome Measurement:** Patients were followed until radiographic union was achieved, with this being the principle determinant of a successful outcome.

**Results:** Radiographic union was achieved in 17 of 18 patients (94%). The average follow-up was 26.5 months (range 12–49 months). The average time from surgery to radiographic union was 5.4 months (range 2.5–8.8 months). There was 1 failure of fixation, and 2 patients developed transient neurologic sequelae. Range of motion measurements obtained from the most recent clinical follow-up were 115 degrees (range 20–180 degrees) active forward elevation, 37 degrees (range 0–70 degrees) passive external rotation, and active internal rotation was to the 10th thoracic vertebrae. American Shoulder and Elbow Surgeon scores improved from a level of 40 preoperatively to 81 postoperatively, and visual analog scale scores improved from 6.7 to 1.5.

**Conclusion:** Intramedullary strut allograft insertion combined with fixed-angle plating is an effective technique for treating viable nonunions of the proximal humerus and was successful in achieving union in 94% of our patients.

**Key Words:** fixed-angle locked plating, nonunions, proximal humeral fractures, structural allograft

(*J Orthop Trauma* 2009;23:173–179)

Proximal humerus fractures account for 5%–8% of all fractures.<sup>1,2</sup> Although more than 80% of these fractures heal without surgical intervention, nonunions do arise with rates varying from less than 1% to as high as 23%.<sup>1,3–7</sup> The classification of nonunions has best been described by Weber and Čech<sup>8</sup> and is based on the overall vitality and healing potential of the bone. According to their classification, nonunions can be categorized as either hypervascular or atrophic. In the hypervascular type, the bone ends are viable and capable of a biologic reaction in the form of either abundant callus formation (elephant foot or horse hoof) or bone absorption (oligotrophic). In the atrophic type, there is no potential for biologic reaction and these are therefore nonviable.

When proximal humeral nonunions do present, they pose a challenge for even the most experienced upper extremity surgeon. The bone quality is frequently poor and the bone stock is often limited. Patients may also typically have multiple confounding comorbidities.<sup>9–18</sup> Although many treatment options have been described, results have been variable with no definitive surgical solution identified.<sup>1,2,4,6,7,12,16,18–30</sup> The purpose of the current article is to retrospectively review the results of 19 patients treated with a new technique recently described by the authors for treatment of viable proximal humeral metadiaphyseal nonunions involving use of a fixed-angle locked plate in conjunction with an intramedullary strut allograft.<sup>31</sup>

## MATERIALS AND METHODS

Between November 2001 and December 2007, 18 patients with viable nonunions of the proximal humeral metadiaphysis presented to the Shoulder and Elbow Services of the senior authors (M.M. and S.P.K.) and subsequently underwent open reduction and internal fixation (ORIF), using a fixed-angle locked plate and an intramedullary strut allograft, for definitive treatment of their nonunion. This technique was previously described by Badman et al.<sup>31</sup> Confirmation of the nonunion was made by both clinical and radiographic

Accepted for publication January 5, 2009.

From the \*Florida Orthopaedic Institute, Shoulder and Elbow Service, Tampa, FL; †Department of Orthopaedics, University of Miami, Miami, FL; and ‡PO Box 016960 (D-27) Miami, FL 33101.

The current authors received no direct funding for the purposes of this study. The Foundation for Orthopedic Research and Education has received grant support from Synthes, Depuy, and UPEX for previous and ongoing projects.

Presented in part at the American Academy of Orthopaedic Surgeons Meeting, San Francisco, CA, 2008.

B.L.B. and M.M. are currently physician consultants for UPEX.

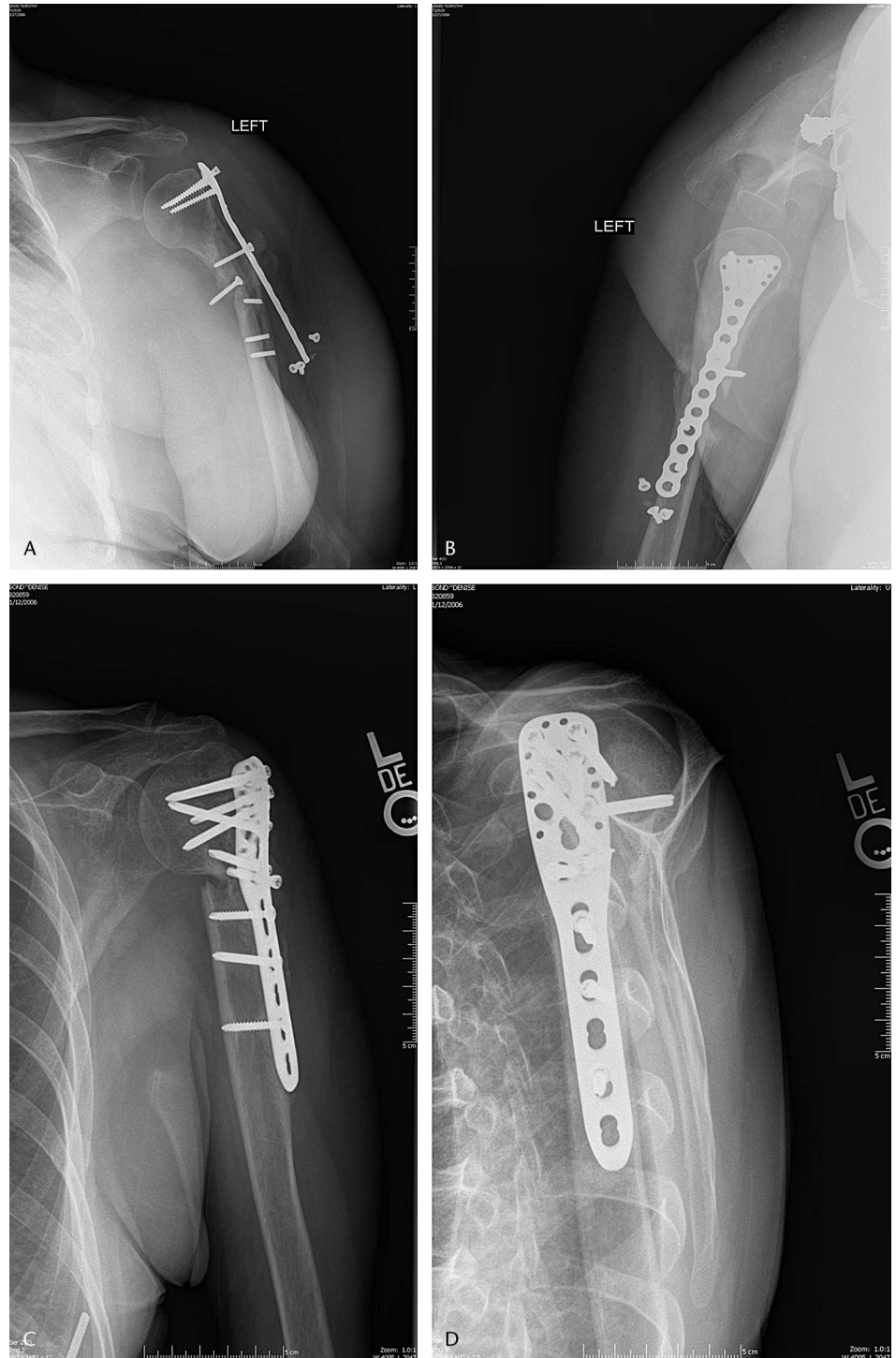
Reprints: Brian L. Badman, MD, 7950 Ortho Drive, Brownsburg, IN 46112 (e-mail: bbadman@gmail.com).

Copyright © 2009 by Lippincott Williams & Wilkins

examinations. Pain was the primary indication in proceeding with operative intervention. The average age of the patients was 60.4 (range 40–84) years, and all patients were female. Patients with severe humeral head bone loss, avascular necrosis, evidence of arthrosis, or less than 12-month follow-up were excluded. Eighteen proximal third metadiaphyseal nonunions were identified (Figs. 1A–D). Eight patients had a history of smoking (7 current and 1 remote) with other

pertinent medical comorbidities including diabetes (5), chronic obstructive pulmonary disease (2), cancer (2), coronary artery disease (1), hypertension (10), and colitis (1) (Table 1).

All patients received their initial treatments at different institutions before presenting to either of the senior authors' services. The primary mechanism of injury was secondary to a fall in 15 patients and was due to motor vehicle accidents in 3 patients. Initial treatments included conservative



**FIGURE 1.** Radiographic case examples of two patients with proximal humeral nonunions.

**TABLE 1.** Data on the Patients

Patient Number	Age/Sex (yrs)	Mechanism	Dominant Arm	Initial Treatment	Weber and Čech Classification	Comorbidities	Delay Between Injury–Operation (mo)	Treatment	Union	Time to Union (mo)	Complications or Additional Surgeries
1	84/F	Fall	Yes	Sling	Oligotrophic	CA, CAD, HTN	27.2	Bent plate	Yes	3.9	None
2	66/F	Fall	Yes	Sling	Oligotrophic	Colitis, remote smoker	4.5	Bent plate	Yes	4.8	None
3	80/F	Fall	Yes	Sling	Hypertrophic nonunion	Osteoporosis	4.9	Bent plate	Yes	5.3	None
4	57/F	Fall	Yes	Blade plate*	Oligotrophic	COPD, smoker	13.0	Bent plate	Yes	5	Radial nerve palsy; capsular release
5	65/F	Fall	No	Fx brace	Oligotrophic	HTN, COPD, CA, smoker	2.2	Bent plate	Yes	5	Radial nerve palsy
6	73/F	Fall	Yes	IM nail	Oligotrophic	HTN, DM	14.7	Bent plate	Yes	8.8	None
7	46/F	MVA	Yes	Blade plate and locked plate	Oligotrophic	Smoker	41.2	Locked plate	No	NA	Nonunion
8	47/F	Fall	Yes	Blade plate	Oligotrophic	HTN, DM, hepatitis, smoker	31.4	Locked plate	Yes	7	Capsular release
9	49/F	Fall	No	Locked plate	Oligotrophic	Smoker	13.3	Locked plate	Yes	7.4	None
10	50/F	MVA	No	Locked plate	Oligotrophic	None	11.0	Locked plate	Yes	5.9	None
11	61/F	Fall	No	IM nail	Oligotrophic	None	10.3	Locked plate	Yes	6.0	None
12	71/F	Fall	Yes	Sling	Oligotrophic	HTN	13.3	Locked plate	Yes	7.9	None
13	63/F	Fall	No	Sling	Oligotrophic	HTN	10.1	Locked plate	Yes	4.0	None
14	58/F	Fall	No	Percutaneous pinning	Oligotrophic	Obese, DM, HTN, smoker	14	Locked plate	Yes	2.5	None
15	53/F	MVA	Yes	Rods + sutures; locked plate	Oligotrophic	HTN, GERD	172	Locked plate	Yes	5.2	None
16	65/F	Fall	Yes	Percutaneous pinning	Oligotrophic	HTN, asthma	28.2	Locked plate	Yes	3.9	None
17	60/F	Fall	Yes	Rush rod	Oligotrophic	HTN, DM, osteoporosis	51.2	Locked plate	Yes	4.5	None
18	40/F	Fall	Yes	IM nail	Oligotrophic	HTN, DM, CAD, breast CA, smoker	23.1	Locked plate	Yes	4.3	None

CA, cancer; CAD, coronary artery disease; COPD, chronic obstructive pulmonary disease; DM, diabetes mellitus; F, female; GERD, gastroesophageal reflux disease; HTN, hypertension; IM, intramedullary; MVA, motor vehicle accident.

\*Failed due to infection; patient was treated after plate removal.

management in 6 patients and surgical intervention in 12 patients. The initial technique selected to manage these fractures included blade plate fixation (3 patients), locked plate fixation (3 patients, including 1 converted from blade plate and 1 converted from Enders rods and suture fixation), percutaneous pinning (2 patients), and intramedullary fixation (4 patients).

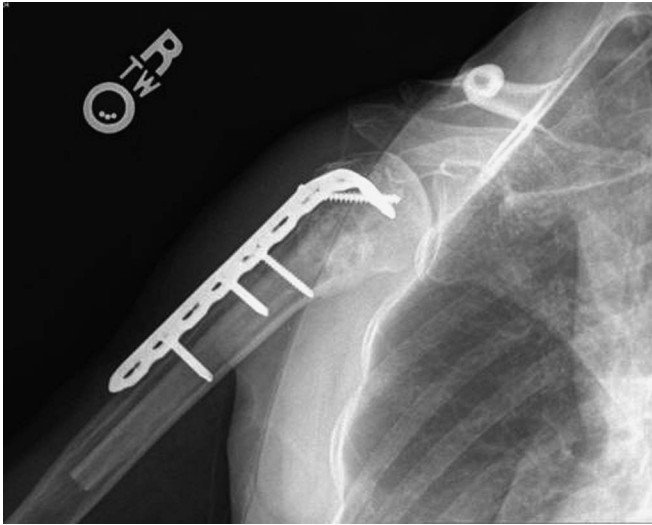
Diagnoses at time of presentation included the following: 17 oligotrophic and 1 hypertrophic nonunions based on the classification of Weber and Čech.<sup>8</sup> The average time from initial injury to treatment of the nonunion was 26.9 months (range 2.2–172 months). The initial 6 patients were treated with a modified large fragment locking plate that was bent 90 degrees at the proximal end to allow for impaction into the head and to provide a minimum of 3 points of fixation into the proximal fragment (Fig. 2). The remaining 12 patients were treated with an anatomic proximal humeral locking plate. An intramedullary cortical allograft (fibula or ulna) was used in all patients (Fig. 3). Morselized allograft cancellous bone and demineralized bone matrix was used as an adjunct in 4

patients. Suture fixation of the tuberosities with attachment to the plate was used as needed (Fig. 4).

In all cases, the shoulder was immobilized postoperatively. Formal therapy commenced with the first sign of radiographic union. A retrospective review of the medical charts and radiographs was then performed to obtain the data for the current series. At each routine follow-up visit, all patients were assessed by the 2 senior authors through patient interview, physical examination, and patient survey. This information was then used and tabulated into a shoulder rating score according to the American Shoulder and Elbow Surgeons that was obtained at each visit. Subjective degrees of patient pain and satisfaction were obtained through a visual analog scale, which also was completed at each routine visit.

## RESULTS

Radiographic union was achieved in 17 of 18 patients (94%) using the current surgical technique (Figs. 5A–D). The average follow-up was 26.5 months (range 12–49 months).



**FIGURE 2.** Radiographic example of modified large locking plate bent 90 degrees at tip with impaction into head.

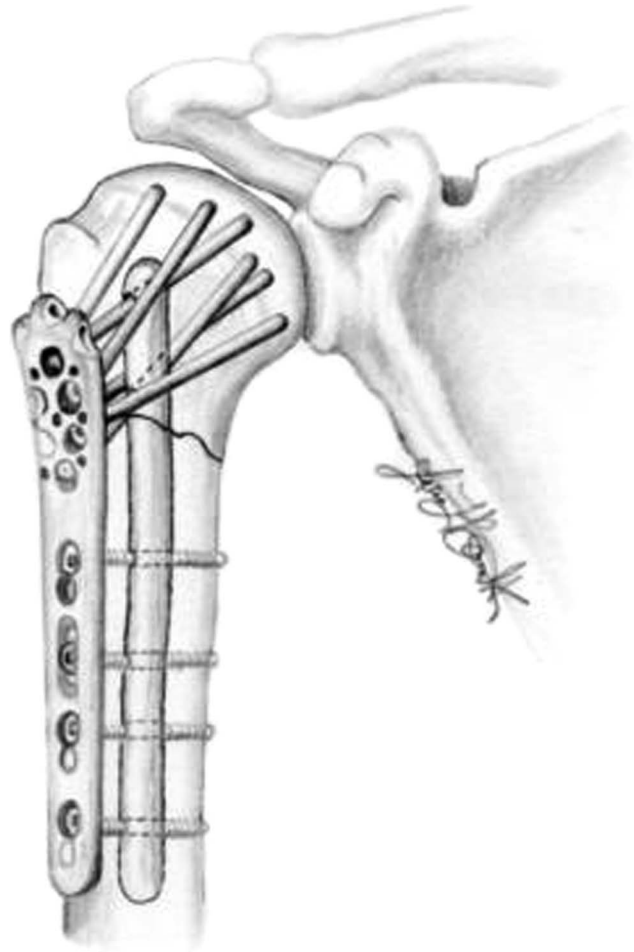
The average time from revision surgery to the date of radiographic union was 5.4 months (range 2.5–8.8 months). There was 1 failure in the group attributable to persistent nonunion and plate breakage noted at 9 months postoperatively. This patient (patient 9) was a heavy smoker (1 pack per day) who had failed 2 previous attempts at ORIF, and, upon her third failure, was converted to a hemiarthroplasty (Table 1).

Range of motion measurements were obtained and averaged from the most recent clinical follow-up visit. The average active forward flexion was 115 degrees (range 20–180 degrees), passive external rotation averaged 37 degrees (range 0–70 degrees), and active internal rotation averaged to the 10th thoracic vertebrae. Excluding 1 patient with a massively deficient rotator cuff, shoulder elevation averaged 121 degrees (range 70–180 degrees). In regard to objective outcome measurements, the American Shoulder and Elbow Surgeon score improved from an average score of 40 preoperatively to 81 postoperatively. The pain score on the visual analog scale improved from an average of 6.7 before surgery to 1.5 after surgery. All patients with united fractures reported being satisfied with their final outcome (Table 2).

There were no postoperative infections. Two patients developed a posterior cord neuropraxia that resolved within 3 months. The etiology of the nerve palsy in each patient was not entirely clear and thought to be potentially attributable due to either the regional anesthetic block or iatrogenic stretch of the posterior cord of the brachial plexus that may have occurred with the exposure due to an altered surgical field. Two patients were identified with severe posttraumatic capsulitis. These patients were dissatisfied with their limited motion and elected to undergo arthroscopic capsular release after union was achieved.

## DISCUSSION

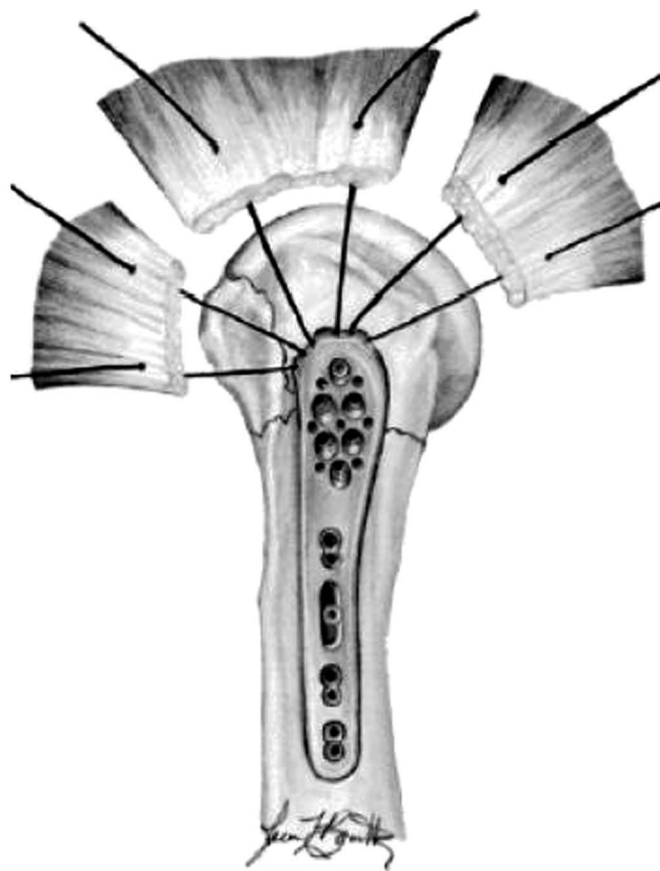
The proper approach to treating nonunions should first involve the identification of the type of nonunion that is encountered. As first described by Weber and Čech<sup>8</sup> more than 30 years ago and recently discussed by Frölke and Patka,<sup>32</sup>



**FIGURE 3.** Locking plate with intramedullary dowel.

nonunions are best classified as either viable or nonviable. Viable nonunions have the potential for bone healing but typically lack the mechanical environment necessary for fracture union. They will commonly show increased activity on bone scan and radiographically will demonstrate callus formation or bone resorption at the fracture ends. Nonviable nonunions lack the biologic activity necessary for bone union. The bone ends are inert and devitalized and will be characterized by poor activity on bone scan and no radiographic change over long periods. Treatment is therefore predicated on the type of nonunion present; viable nonunions require improved fracture stability through better fixation techniques to improve the mechanical environment and minimize motion through the fracture site, whereas nonviable nonunions require debridement of devitalized bone to improve the biologic activity and provide for osteosynthesis. Our current series dealt specifically with viable nonunions.

Although not all patients with humeral nonunions are clinically symptomatic, those presenting with symptoms are typically severely disabled by pain and loss of motion.<sup>2,6,7,12,18–20</sup> Historically, the initial approach to treating proximal humeral nonunions involved ORIF. Due to the inherent difficulties of obtaining stable fixation in compromised bone, standard plating techniques have been associated with failure rates as



**FIGURE 4.** Suture fixation of tuberosities and attachment to plate thru suture eyelets.

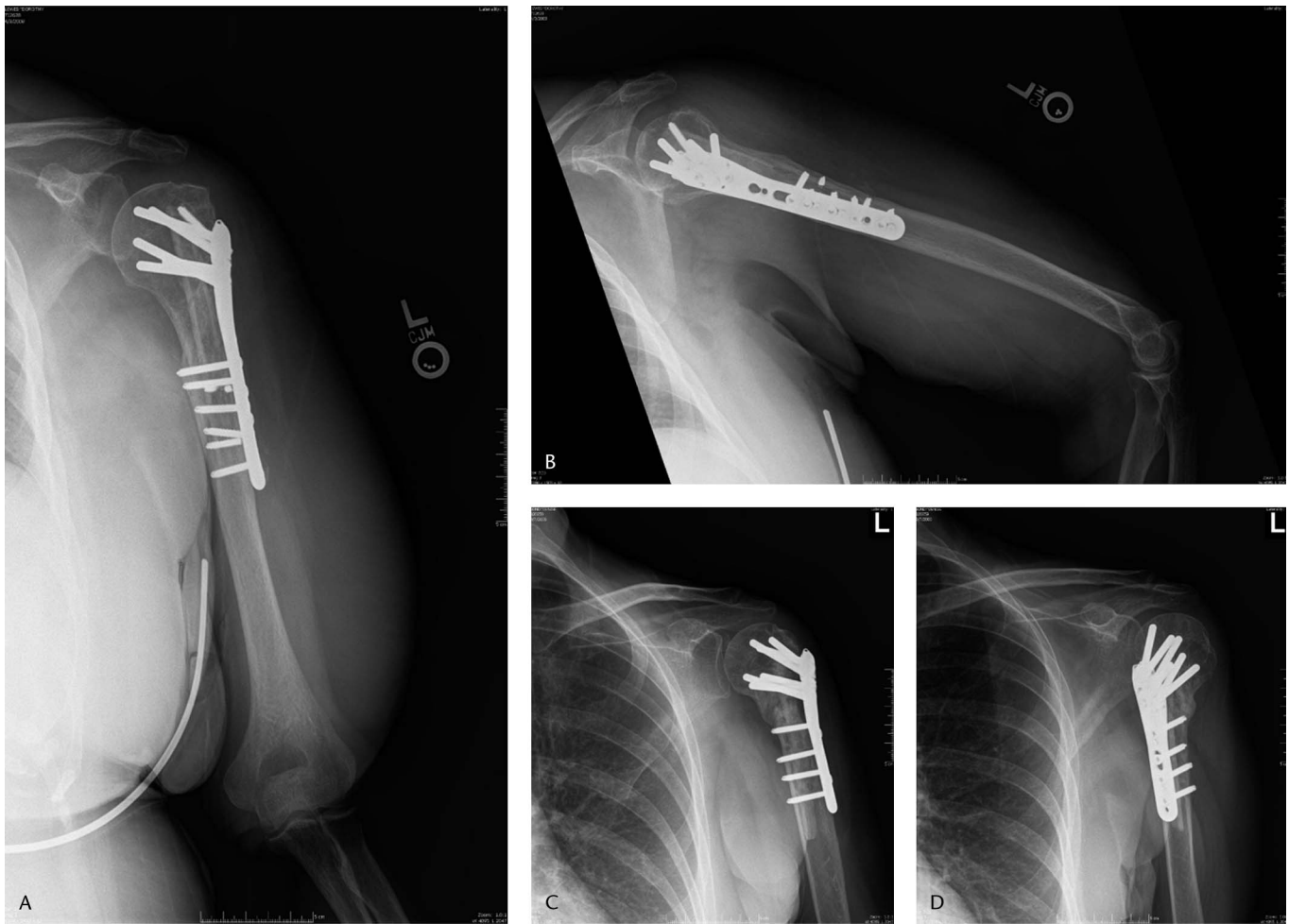
high as 70%.<sup>24,27</sup> As a result, several authors have proposed multiple alternative techniques with variable outcomes including screw augmentation with polymethylmethacrylate, tension banding of the rotator cuff with extramedullary plates or intramedullary nails, bone grafting with autograft struts, standard plate modification into a blade plate construct, and hemiarthroplasty.<sup>1,2,4,6,7,12,16,18–30</sup> Although several of these techniques have resulted in improved union rates in small series, many have not been equally reproducible, and at times, they have been associated with added patient morbidity. Neer<sup>29</sup> was able to achieve a 92% union rate with the use of intramedullary rods and tension banding of the rotator cuff in 13 patients, but all required a second operation for implant removal due to pain and stiffness. By comparison, both Nayak et al and Duralde et al used a similar tension banding technique but were unable to achieve the same success as Neer, noting a 20% and a 43% persistent nonunion rate, respectively. They were however able to achieve similar outcomes in regard to painful implants with more than 75% of patients in both series, requiring further surgery for implant removal.<sup>1,22</sup>

The addition of an autograft has been advocated by several authors with noted improvement in union rates.<sup>1,2,6,7,12,20,22,25,27–30</sup> Despite its known benefits in assisting fracture healing, donor site morbidity secondary to graft harvest remains a consistent problem.<sup>33–40</sup> The most common autograft options include cancellous bone or cortical grafts

from the tibia, fibula, ribs, or ilium. Although quickly resorbed and providing minimal structural support, cancellous bone remains the most prevalently used graft choice. Routinely harvested from the iliac crest, complications related to the donor site are common and include chronic pain, neurologic injury, hematoma, deep infection, hernias, and iliac wing fractures.<sup>33–39</sup> Despite serving as a better graft choice due to their immediate structural stability and added bone stock, cortical grafts are used relatively infrequently due to the difficulties associated with their procurement and the substantial morbidity involved, including harvest site fracture and chronic pain.<sup>27,40</sup>

Based upon the present series and review of the literature, the most consistent technique for treatment of proximal humeral nonunions involves the use of a fixed-angle device in the form of a modified standard plate, a site-specific blade plate, or an anatomic proximal humeral locking plate.<sup>25,26,30</sup> Modification of a standard plate into a fixed-angle device was first described by Bosworth<sup>21</sup> and has since been confirmed to be biomechanically superior to a standard plate when dealing with compromised bone.<sup>41</sup> In one of the larger and more successful nonunion series to date, Ring et al<sup>25</sup> employed both a site-specific blade plate (Synthes Ltd, Paoli, PA) and a modified standard plate in 25 patients and achieved a 92% union rate. With regard to the transition toward the anatomic locking plate, the current authors contend that the difficulties with a modified standard plate or blade plate are that it can be both cumbersome to apply and time consuming to bend, with the potential for implant prominence and persistent pain remaining a concern. Although further long-term outcome studies are required, the potential advantages of the anatomic plate are its lower profile, which may reduce impingement, and its multiple divergent proximal screw options that allow for improved fixation in compromised bone. Recent biomechanical testing has further proven that the locking plate is superior in torsional rigidity and stiffness as compared with a blade plate for 2-part proximal humeral fractures.<sup>42</sup> By increasing the stiffness and reducing the motion at the fracture site, the healing process may be further enhanced by improving the mechanical environment.

Our current series yielded a 94% union rate using a fixed-angle device with the primary technical difference from Ring's series, being the addition of the cortical allograft and a switch to the use of an anatomic proximal humeral locking plate when it became available.<sup>25</sup> Although the addition of a cortical strut has previously been described and successfully used for mid-shaft humeral nonunions, no author to our knowledge has assessed its use with proximal humeral nonunions.<sup>43</sup> The advantages of the allograft strut are that it provides added bone stock to enhance fixation, and its use avoids the complications associated with donor site morbidity from autograft harvesting. Wright demonstrated that screw fixation in the proximal humerus is the weakest region biomechanically in a cadaver humerus.<sup>44</sup> Previous authors have reported that cavitory defects encountered in proximal humeral nonunions are an indication to abort ORIF and to proceed with prosthetic replacement.<sup>28</sup> In all cases of our current series, the bone stock was compromised, and once the nonunion was adequately debrided and the head fragment elevated, a large



**FIGURE 5.** Post-operative radiographs of patients from Figures 1A–1D with healed fractures using locked plate fixation and intramedullary dowel.

**TABLE 2.** Range of Motion and Patient Satisfaction

Patient Number	ROM Forward Flexion (Degrees)	ROM External Rotation (Degrees)	Satisfaction
1	160	60	No pain
2	180	50	No pain
3	180	60	No pain
4	150	60	Mild pain
5	110	70	No pain
6	20	50	No pain
8	130	45	Mild pain
9	170	40	Mild pain
10	100	40	Mild pain
11	90	10	No pain
12	90	45	Mild pain
13	90	5	Moderate pain
14	120	5	No pain
15	120	45	No pain
16	90	10	Mild pain
17	70	0	Mild pain

ROM, range of motion.

metaphyseal void was routinely present. One criticism of our present series is that we elected to use an allograft fibular strut to treat established nonunions rather than autograft iliac crest graft. The current authors would contend that the present series included all viable nonunions where the mechanical environment was not favorable to fracture healing. Given this circumstance, the strut serves as a void filler, allowing for improved fixation, added bone stock, support of the head fragment, and an overall better mechanical environment favorable for bone healing. In situations where a nonviable nonunion is present, we would agree that autograft bone to enhance the biologic milieu may be of vital importance.

Previous authors have reported that cavitory defects encountered in proximal humeral nonunions are an indication to abort ORIF and to proceed with prosthetic replacement.<sup>28</sup> Although hemiarthroplasty or even reverse shoulder replacement remains potential option in situations where the head is severely compromised (such as with head-splitting fractures or when only a thin shell of cortical bone remains), the authors feel that preservation of the native joint is critical in the younger patient due to the inherent failures of prosthetic replacement in this population. We also feel that the reverse

shoulder replacement is a salvage procedure, and until further long-term outcome data are made available, this should be used sparingly and only in the situation of the older patient greater than the age of 70 years when all else have failed. Although an inherent risk of disease transmission exists with allograft bone, with the implementation of stricter screening processes and the avoidance of unprocessed fresh-frozen grafts, their use is safe with only 1 case report of hepatitis C transmission from a processed graft noted and there were no documented reports of human immunodeficiency virus transmission.<sup>45,46</sup>

Although fortunately rare, proximal humeral nonunions are a devastating problem that poses a challenge for the treating orthopaedist. In our hands, the current technique has provided a safe and reliable way of achieving union in 94% of patients and it has eliminated the pitfalls associated with autograft harvesting. Despite improvement in union, patients will continue to struggle with range of motion and stiffness as evident in our current study with the average forward flexion being only 115 degrees. A strong understanding should be made between the patient and the physician that further surgery may be needed once union is obtained and that despite further measures, the motion may remain permanently limited.

## REFERENCES

- Nayak NK, Schickendantz MS, Regan WD, et al. Operative treatment of nonunion of surgical neck fractures of the humerus. *Clin Orthop Relat Res.* 1995;313:200–205.
- Volgas DA, Stannard JP, Alonso JE. Nonunions of the humerus. *Clin Orthop Relat Res.* 2004;419:46–50.
- Einarsson F. Fracture of the upper end of the humerus. Discussion based on the follow-up of 302 cases. *Acta Orthop Scand.* 1958;27(Suppl 32):1–215.
- Neer CS II, Rockwood CA. Fractures and dislocations of the shoulder. In: Rockwood CA Jr, Green DD, eds. *Fractures*. Vol 1. Philadelphia, PA: J. B. Lippincott; 1975:610.
- Neer CS II. Displaced proximal humeral fractures. Part I. Classification and evaluation. *J Bone Joint Surg Am.* 1970;52A:1077.
- Scheck M. Surgical treatment of nonunions of the surgical neck of the humerus. *Clin Orthop Relat Res.* 1982;167:255–259.
- Sorensen KH. Pseudoarthrosis of the surgical neck of the humerus. *Acta Orthop Scand.* 1964;34:132–138.
- Weber BG, Čech O. *Pseudoarthrosis, Pathology, Biomechanics, Therapy, Results*. Bern, Switzerland: Hans Huber; 1976.
- Coventry MB, Laumen EL. Ununited fractures of the middle and upper humerus: special problems in treatment. *Clin Orthop Relat Res.* 1970;69:192–198.
- Epps CH Jr, Cotler JM. Complications of treatment of fractures of the humeral shaft. In: Epps CH Jr, ed. *Complications in Orthopaedic Surgery*. 2nd ed. Philadelphia, PA: J. B. Lippincott; 1986:277–304.
- Gristina AG. Management of displaced fractures of the proximal humerus. *Contemp Orthop.* 187;15:61–93.
- Leach RE, Premer RF. Nonunion of the surgical neck of the humerus: method of internal fixation. *Minn Med.* 1965;48:318–322.
- Mayer PJ, Everts CM. Nonunion, delayed union, malunion and avascular necrosis. In: Epps CH Jr, ed. *Complications in Orthopaedic Surgery*. 2nd ed. Philadelphia, PA: J. B. Lippincott; 1986:207–230.
- Muller ME, Thomas RJ. Treatment of nonunion in fractures of long bones. *Clin Orthop Relat Res.* 1979;138:141–153.
- Paavolainen P, Bjorkenheim JM, Slatys P, et al. Operative treatment of severe proximal humeral fractures. *Acta Orthop Scand.* 1983;54:374–379.
- Ray RD, Sankaran B, Fetrow KO. Delayed union and nonunion of fractures. *J Bone Joint Surg Am.* 1964;46:627–643.
- Rooney PJ, Cockshott WP. Pseudoarthrosis following proximal humeral fractures: a possible mechanism. *Skeletal Radiol.* 1986;15:21–24.
- Wirth MA. Late sequelae of proximal humerus fractures. *Instr Course Lect.* 2003;52:13–16.
- Antuna SA, Sperling JW, Sanchez-Sotolo J, et al. Shoulder arthroplasty for proximal humeral nonunions. *J Shoulder Elbow Surg.* 2002;11:114–121.
- Healy WL, Jupiter JP, Kristiansen TK, et al. Nonunion of the proximal humerus. A review of 25 cases. *J Orthop Trauma.* 1990;4:424–431.
- Bosworth DM. Blade plate fixation: technique suitable for fractures of the surgical neck of the humerus and similar lesions. *JAMA.* 1949;141:1111–1113.
- Duralde XA, Flatow EL, Pollock RG, et al. Operative treatment of nonunions of the surgical neck of the humerus. *J Shoulder Elbow Surg.* 1996;5:169–180.
- Neer CS II. Displaced proximal humeral fractures. Part II. Treatment of three-part and four-part displacements. *J Bone Joint Surg Am.* 1970;52A:1090.
- Norris TR, Turner JA, Bovill D. Nonunion of the upper humerus: an analysis of the etiology and treatment in 28 cases. In: Post M, Morrey BF, Hawkins RJ, eds. *Surgery of the Shoulder*. St. Louis, MO: Mosby; 1990:63–67.
- Ring D, McKee M, Perey B, et al. The use of a blade plate and autogenous cancellous bone graft in the treatment of ununited fractures of the proximal humerus. *J Shoulder Elbow Surg.* 2001;10:501–507.
- Sehr JR, Szabo RM. Semitubular blade plate fixation in the proximal humerus. *J Orthop Trauma.* 1988;2:327–332.
- Walch G, Badet R, Nove-Josserand L, et al. Nonunions of the surgical neck of the humerus: surgical treatment with an intramedullary bone peg, internal fixation, and cancellous bone grafting. *J Shoulder Elbow Surg.* 1996;5:161–168.
- Xavier AD, Flatow EL, Pollack RG, et al. Operative treatment of nonunions of the surgical neck of the humerus. *J Shoulder Elbow Surg.* 1996;5:169–180.
- Neer CS II. Nonunion of the surgical neck of the humerus. *Orthop Trans.* 1983;7:389.
- Jupiter JB, Mullaji AB. Blade plate fixation of proximal humeral nonunions. *Injury.* 1994;25:301–303.
- Badman BL, Mighell M, Drake GN. Proximal humeral nonunions: surgical technique with fibular strut allograft and fixed-angle locked plating. *Tech Shoulder Elbow Surg.* 2006;7(2):95–101.
- Frölke JP, Patka P. Definition and classification of fracture non-unions. *Injury.* 2007;38S:S19–S22.
- Heary RF, Schlenk RP, Sacchieri TA, et al. Persistent iliac crest donor site pain: independent outcome assessment. *Neurosurgery.* 2002;50:510–516, discussion 516–517.
- Goulet JA, Senunas LE, DeSilva GL, et al. Autogenous iliac crest bone graft. Complications and functional assessment. *Clin Orthop Relat Res.* 1997;339:76–81.
- Hill NM, Horne JG, Devane PA. Donor site morbidity in the iliac crest bone graft. *Aust N Z J Surg.* 1999;69:726–728.
- Silber JS, Anderson DG, Daffner SD, et al. Donor site morbidity after anterior iliac crest bone harvest for single-level anterior cervical discectomy and fusion. *Spine.* 2003;28:134–139.
- Arrington ED, Smith WJ, Chambers HG, et al. Complications of iliac crest bone graft harvesting. *Clin Orthop Relat Res.* 1996;329:300–309.
- Robertson PA, Wray AC. Natural history of posterior iliac crest bone graft donation for spinal surgery: a prospective analysis of morbidity. *Spine.* 2001;26:1473–1476.
- Velchuru VR, Satish SG, Petri GJ, et al. Hernia through an iliac crest bone graft site: report of a case and review of the literature. *Bull Hosp Jt Dis.* 2006;63(3–4):166–168.
- Vail TP, Urbaniak JR. Donor-site morbidity with use of vascularized autogenous fibular grafts. *J Bone Joint Surg Am.* 1996;78:204–211.
- Instrum K, Fennell C, Shrive N, et al. Semitubular blade plate fixation in proximal humerus fractures: a biomechanical study in a cadaveric model. *J Shoulder Elbow Surg.* 1998;7:462–468.
- Weinstein DM, Bratton DR, Ciccone WJ, et al. Locking plates improve torsional resistance in the stabilization of three-part proximal humeral fractures. *J Shoulder Elbow Surg.* 2006;15:239–243.
- Wright TW, Miller GJ, VanderGriend RA, et al. Reconstruction of the humerus with an intramedullary fibular graft. A clinical and biomechanical study. *J Bone Joint Surg Br.* 1993;75:804–807.
- Wright TW. Treatment of humeral diaphyseal nonunions in patients with severely compromised bone. *J South Orthop Assoc.* 1997;6:1–7.
- AATB information alert. McLean, VA: American Association of Tissue Banks; 1993.
- Trotter RF. Transmission of hepatitis C by implantation of a processed bone graft. *J Bone Joint Surg Am.* 2003;85:2215–2217.