

## REVIEW

# Proximal Humeral Nonunions: Surgical Technique with Fibular Strut Allograft and Fixed-Angle Locked Plating

Brian Lowell Badman, MD  
Hendricks Regional Hospital  
8244E US Highway 36  
Suite 1260 Avon, IN

Mark Mighell, MD  
Florida Orthopedic Institute  
13020 N, Telecom Parkway  
Temple Terrace, Tampa, FL

Gregory N. Drake, DO  
Orthopedic Surgery, Bostford General Hospital  
28050 Grand River Ave.  
Farmington Hills, MI

## ■ ABSTRACT

Nonunions of the proximal humerus, although uncommon, are challenging for even the experienced upper extremity specialist. The bone quality is typically poor, and the proximal bone stock is limited. These patients often possess multiple comorbidities contributing to the development of the nonunion. Although many treatment options exist, results have been mixed with no definitive surgical technique identified. The technique presented is a safe and reliable method for treatment of nonunions of the proximal humerus using an inlay fibular strut allograft, compression through the nonunion site with heavy suture, and secure fixation with a fixed-angle locked plate.

**Keywords:** proximal humerus nonunions, fibular strut allograft, locked plating, fixed-angle plate

## ■ HISTORICAL PERSPECTIVE

Proximal humerus fractures are relatively common accounting for 5% to 8% of all fractures.<sup>1,2</sup> Although more than 80% of these heal with no surgical intervention, displaced unimpacted surgical neck fractures

are associated with a higher incidence of nonunion with rates varying from less than 1% to as high as 23%.<sup>1,3-7</sup> Common predisposing factors contributing to the development of the nonunion include smoking, alcoholism, diabetes mellitus, soft tissue interposition, extensive comminution, hanging arm casts, poor surgical technique, or any combination thereof.<sup>8-17</sup> Although not all patients with humeral nonunions are clinically symptomatic, those presenting with symptoms are typically severely disabled by pain and loss of motion.<sup>2,6,7,11,17-19</sup>

The historical approach to treatment of proximal humeral nonunions has typically involved open reduction and internal fixation. Several techniques have been described with no superior solution identified. Reported techniques include standard plate-and-screw fixation, screw augmentation with polymethylmethacrylate, tension banding of the rotator cuff with extramedullary plates or intramedullary nails, bone grafting with autograft struts, and standard plate modification into a blade plate construct.<sup>1,2,4,6,7,11,15,17,19-26</sup> Many of the alternative techniques arose out of high failure rates with early standard plating.

Neer and Rockwood<sup>4</sup> first recommended tension band technique with intramedullary rods to facilitate head compression and improve stability. Despite better union rates with this technique, Nayak et al<sup>1</sup> noted both a 20% incidence of persistent nonunion and avascular

Reprints: Brian Lowell Badman, MD, Hendricks Regional Hospital, 8244 E US Highway 36, Suite 1260 Avon, IN (e-mail:blbadman@yahoo.com).

necrosis and an 80% incidence of subsequent hardware removal secondary to pain. The addition of bone graft via various autografting techniques has also resulted in improved union rates at the expense of patient morbidity. Walch et al<sup>26</sup> first proposed an intramedullary bone peg technique whereupon a corticocancellous graft was harvested from the patient's iliac crest, anterior tibia, or fibula to supplement fixation with rush rods or screws. Although a 96% union rate was achieved, donor site morbidity was substantial with 50% of patients developing a pathological fracture after harvesting from the anterior tibial crest. Other authors have strictly used iliac crest bone graft; however, donor site morbidity can be substantial with a relatively high incidence of persistent pain postoperatively.<sup>19,23,24,27</sup>

Based on published series, the best overall success for treatment of humeral nonunions involves the use of fixed-angle devices and bone grafting. Plate modification into fixed-angle devices enhances fixation in the humeral head and has frequently been advocated, owing to better biomechanical strength and improved overall results.<sup>8,20,25</sup> Most recently, Ring et al used a site-specific blade (Synthes Ltd, Paoli, PA) plate with autogenous cancellous bone graft in 25 ununited fractures and noted a 92% union rate with 80% of the results considered good to excellent.<sup>24</sup> Even in this series, 2 patients reported complications as a result of their iliac crest harvest.

The purpose of the current article is to present a technique using a precontoured fixed-angle locked plate in conjunction with an inlay allograft fibular strut. Use of an allograft fibular strut has previously been described for midshaft diaphyseal fractures, but to date, it has not been reported for use in proximal humeral nonunions.<sup>28</sup> The technique described herein provides rigid fixation and eliminates the problems associated with donor site morbidity secondary to autograft harvesting.

## ■ INDICATIONS AND CONTRAINDICATIONS

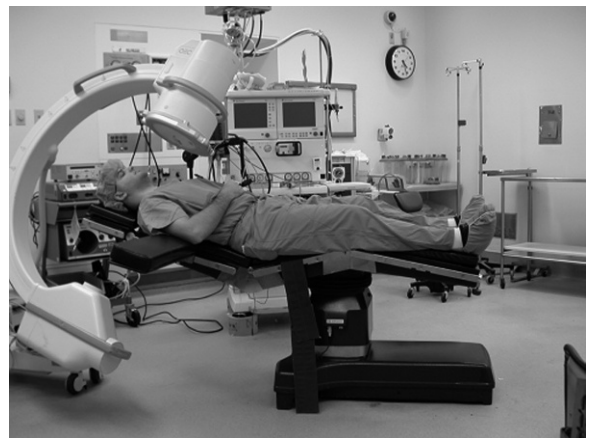Patients presenting with a nonunion usually have variable degrees of disability resulting from pain, instability, loss of motion, or any combination of these.<sup>2,6,7,11,17-19</sup> Indications for operative intervention, first, depends on confirmation of a nonunion based on radiographic and clinical examination. Because not all nonunions are symptomatic, the degree of disability and pain are also important factors in determining the need for surgery. In those patients in severe discomfort with limited resultant use of their extremity, surgery is warranted. In patients with minimal pain and only a moderate loss of function, nonoperative measures may be more appropriate. Because of the extensive nature of

the surgical procedure, the patient's overall health should be tolerable of an operative procedure.

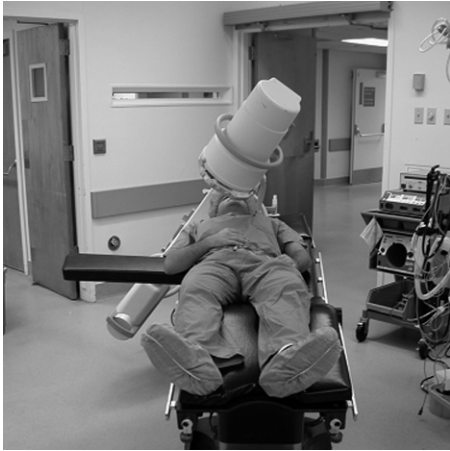## ■ PREOPERATIVE PLANNING

A thorough history and physical examination are essential in all patients being evaluated for proximal humeral nonunion. Important information ascertained includes hand dominance, preinjury functional level, range of motion, neurovascular examination, soft tissue examination, previous surgical procedures relating to nonunion, and examination of the contralateral extremity. All patients in our clinic are required to fill out the American Shoulder and Elbow Society assessment questionnaire. This facilitates assessment of the patient's preoperative functional level and incorporates a visual pain analogue scale that can be used for outcomes analysis. Risks and benefits of surgery should also be discussed at length with an emphasis and understanding that the affected extremity will never be "normal" when compared with the uninvolved limb.

In addition to clinical examination, radiographic analysis is also essential. A standard shoulder series, including a true anteroposterior shoulder, scapular lateral, and axillary views, are recommended. In tolerant patients, internal and external rotation views of the humerus may also be useful. Computed tomography scans, although not routinely necessary, can be helpful for comminuted fractures in which fragment and tuberosity size are difficult to ascertain on plain imaging alone or in fractures with humeral shaft extension to assist in preoperative templating for lag screw placement. Magnetic resonance imaging has not been proven useful in our experience.



**FIGURE 1.** Fluoroscopic setup and patient positioning.



**FIGURE 2.** Fluoroscopic setup and patient positioning.

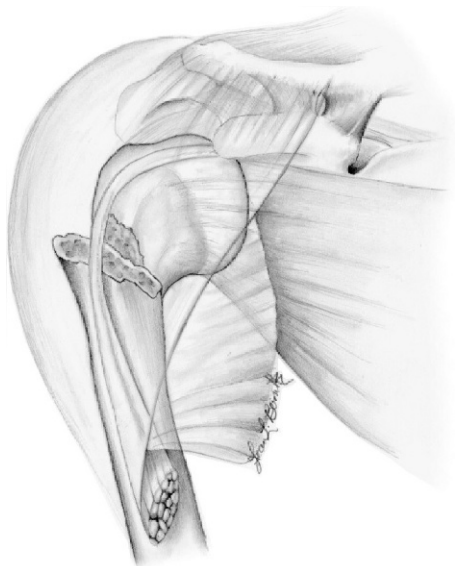
## ■ TECHNIQUE

### Anesthesia

Most of our patients are given an interscalene block for postoperative pain relief coupled with general anesthesia. An interest should be taken in the placement of the endotracheal tube after the patient is intubated. The tube should be taped and secured on the lip contralateral to the side of surgery so as to not hinder the surgery or become dislodged during retractor positioning.

### Positioning

A systematic approach to patient positioning is crucial for adequate intraoperative fluoroscopy. At our institution, we use a regular operative table with a radiolucent



**FIGURE 3.** Standard deltopectoral approach for 2-part nonunion.

footplate (standard on most operating room tables). The table is then rotated so that the patient's head is at the foot of the bed, and the shoulder rests upon the radiolucent footplate. Most operating-room beds are rated for 300 lb and can safely accommodate most patients in this position. After anesthesia is administered, the patient's bottom is placed in the break of the table, and, using a modified beach-chair position, the patient's head is elevated 30 degrees. A pillow is placed below the patient's knees for comfort, and all prominences are well padded. The large C-arm is then positioned parallel to the patient at the head of the bed, avoiding interference with the anesthesiologist (Figs. 1, 2). This simplifies the use of fluoroscopy and allows an unobstructed view of the shoulder intraoperatively with minimal repositioning of the C-arm. Imaging should be obtained before preparing the patient, and if a good image is not easily obtained, the patient should be repositioned.

### Approach

A standard deltopectoral approach to the proximal humerus is used for exposure (Fig. 3). We typically take the cephalic vein medially to prevent inadvertent injury from retractor placement. Gelpi retractors are placed initially to aid subcutaneous exposure, and the spaces are developed. After release of the subdeltoid space, a Browne deltoid retractor is carefully placed under the muscle to facilitate exposure. The clavicular fascia is identified and released. The subcoracoid space is then developed, and the axillary nerve is identified by gentle palpation. If necessary, up to 20% of the lateral conjoint tendon may be released off the tip of the coracoid to facilitate exposure. We avoid placement of retractors under the conjoint tendon to prevent inadvertent stretch of the musculocutaneous nerve. The biceps tendon is then palpated deep to the pectoralis major muscle. If the biceps is interposed



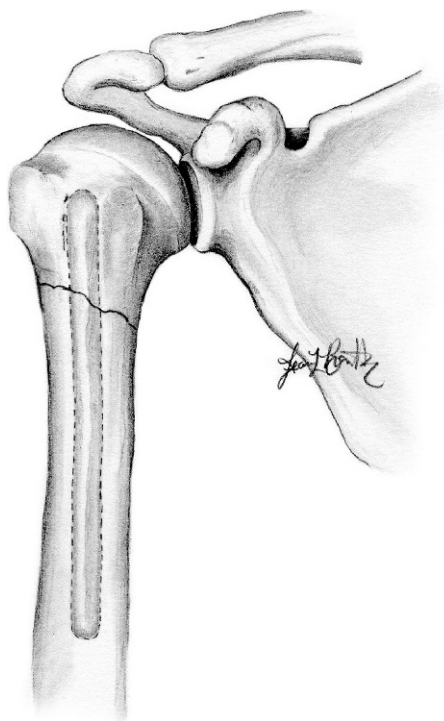
**FIGURE 4.** Krackow locking stitch placed into the subscapularis and infraspinatus tendons.



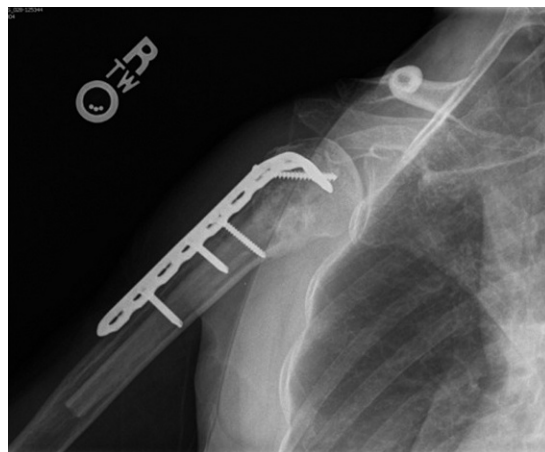
between the fracture fragments, it is mobilized. Initial attempts are made to preserve the tendon as this is a useful landmark for eventual reduction and plate placement. If the biceps tendon is frayed or appears at risk for rupture, we perform a subpectoral tenodesis after fixation of the nonunion to eliminate a source of potential pain and to prevent the possibility of postoperative rupture. The pectoralis is also not routinely released but may be at its upper border to facilitate exposure. Next, the subscapularis and infraspinatus are identified. If the patient has a nonunion of the surgical neck, locating these landmarks is usually not difficult. The tendons are tagged with a Krackow stitch using a no. 2 FiberWire (Arthrex Inc, Naples, FL; Fig. 4). The humeral head and tuberosities can now be mobilized using the suture fixation in the front and back of the rotator cuff. These sutures also aid in fracture manipulation, compression, and reduction and ultimately will counter the natural deforming forces of the rotator cuff.

### Nonunion Preparation

The nonunion site is identified. The interposing scar and fibrous tissue are meticulously debrided with sharp dissection. Once the medullary canal is exposed, curettes and rongeurs may be used to remove additional fibrous tissue and avascular bone. Once adequate debridement of soft tissue has been established, a 3- or



**FIGURE 5.** Fibular graft placed intramedullary with reduction of the humeral head on the shaft.

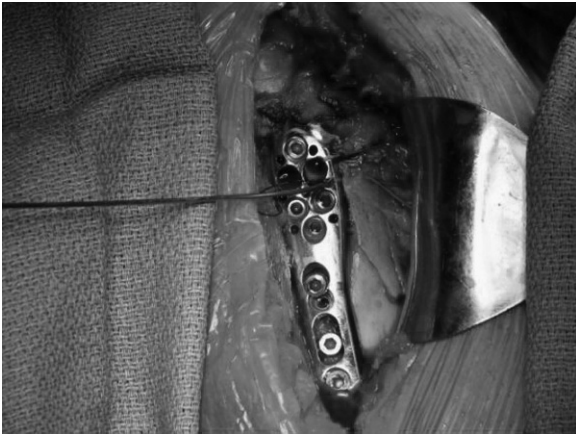

**FIGURE 6.** Locked plate bent 90 degrees at tip and used as blade plate with impaction into the humeral head.

4-mm burr can be used to remove any remaining sclerotic bone and to widen the medullary canal of the upper shaft. Copious irrigation should be used during this process to avoid any thermal necrosis. Extensive preparation of the humeral head is usually not necessary because of the soft cancellous nature of the bone and the resultant ease of impaction of the head on the graft.

### Dowel Preparation and Insertion

A fibular allograft is selected and fashioned on the back table with the intent on using it to stabilize the humeral head and fill the humeral canal. A combination of an oscillating saw and burr can be helpful to cut the graft to the appropriate length and diameter. To assess the appropriate length, we have found that the dowel should extend at least 2 cortical diameters below the fracture site. We “bulletize” the cephalad portion of the graft to facilitate impaction into the cancellous bone of the humeral head. To insert the fibular allograft, the humeral shaft is delivered by extending the arm. The fibular dowel is gently inserted into the medullary canal leaving approximately 2-cm proud onto which the humeral head will be impacted. If the proximal humerus is comminuted, large cortical fragments can be reduced with bone tenacula. When possible, the fragments are fixated to the shaft with lag screws. Alternatively, they can be provisionally held with Kirschner wires and later secured with lag screws placed through the plate. The humeral head is then impacted on the allograft shaft composite (Fig. 5). To facilitate proper rotation, the biceps tendon is a key surgical landmark, as the bicipital groove can be lined up and the proper orientation can be established. Using the previously placed locking sutures in the subscapularis and supraspinatus tendons, the head is rotated into the appropriate position and provisionally pinned to the shaft. Reduction of the fracture and

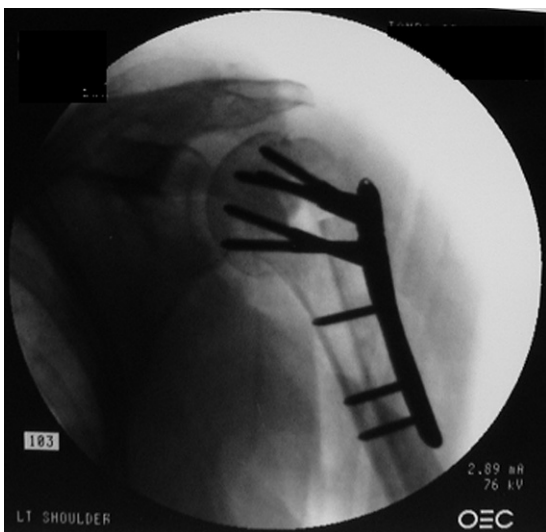

**FIGURE 7.** Locking plate with the tuberosities and head reduced provisionally pinned lateral to the bicipital groove.

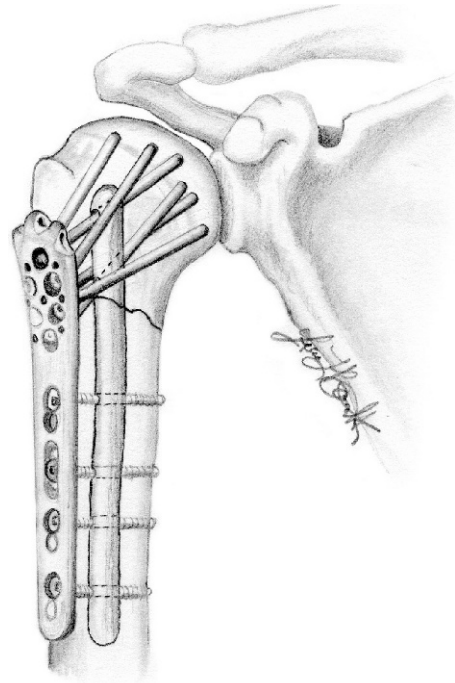
appropriate orientation of the humeral head are now confirmed with fluoroscopy, and adjustments are made.

### Plating

To enhance fixation into the humeral head, we advocate a fixed-angle device or a plate with multiple divergent locking screws. We feel that this is important, given the bone loss and osteoporosis that are typical with established nonunions. Initially, our treatment consisted of modifying of a 4.5 large fragment Synthes (Synthes, Ltd) locking plate by bending the proximal tip nearly 90 degrees and then using this as a blade plate and impacting the bent segment into the humeral head (Fig. 6). More recently, we have adopted the use of a precontoured proximal humeral locking plate. Several plates by various manufacturers, including Synthes and Hand Innovations (Miami, FL), are currently available.



**FIGURE 8.** Fluoroscopic image of reduced nonunion with locked plate fixation and intramedullary fibular allograft.



**FIGURE 9.** Final fixation with fibular allograft and fixed-angled locked plate and passage of screws through the graft.

Design aspects important in plate selection include a low profile to minimize overhead impingement, divergent proximal locking screw options to improve fixation in the head, and suture eyelets to aid with tuberosity compression and fixation.

The plate is applied in standard recommended fashion after satisfactory provisional reduction is confirmed by fluoroscopy. Typically, this requires positioning of the plate lateral to the bicipital groove and 2 to 3 cm distal to the top of the head (Fig. 7). Provisional fixation with Kirschner wires is usually performed first to allow for adjustments of the plate position after fluoroscopic evaluation. Once appropriate position is confirmed, the shaft screws are drilled in standard fashion followed by drilling and placement of the locking screws in the head. While drilling the head, fluoroscopy is used to avoid inadvertent articular penetration and to assist in screw sizing. All holes are subsequently filled, and final fluoroscopy is used to assure adequate length of all screws and acceptable reduction (Fig. 8). Of note, with use of the intramedullary dowel, far superior fixation is obtained if the screws traverse the allograft, thereby creating a more rigid construct (Fig. 9).

### Tuberosity Fixation

We believe that tuberosity fixation to the plate is critical to the overall fracture stability. Much like the principles

used with hemiarthroplasty for fracture, fixation of the tuberosities helps counter the muscular forces of the contracting rotator cuff. Plates with suture eyelets at the proximal portion are advantageous in this regard to facilitate fixation. Using the FiberWire suture previously placed through the subscapularis and supraspinatus tendons, the sutures are passed through the eyelets and secured to the plate. If a standard plate is chosen without this eyelet option, the sutures can be placed through the holes of the plate. We strongly believe that it is imperative not to skip this step. After tuberosity fixation, the fracture is mobilized to assess stability, and final fluoroscopic imaging is obtained. The wound is closed in standard fashion, and a shoulder immobilizer is applied.

### ■ COMPLICATIONS

An ongoing investigation to date has demonstrated a clinical and radiographic healing rate of 100% in 8 surgical neck nonunions treated at our institution. No complications in our experience have been noted. Although there is a theoretical risk of disease transmission from the allograft, with the advent of stricter screening processes, the literature suggests that this is minimal, and, by using a freeze-dried product, the concern is further mitigated. Another potential complication that could occur during placement of the dowel is fracturing the humerus via the stress riser effect of the graft in the distal shaft. Although this has not occurred in our hands, we do encourage tapering the graft and sizing it with the burr to avoid this problem.

### ■ POSTOPERATIVE MANAGEMENT

Patients are admitted 1 to 2 days postoperatively for pain relief and 24 hours of intravenous antibiotics. A shoulder immobilizer is strictly used for 1 to 2 weeks after which gentle pendulum exercises are instituted at home by the patient. No formal therapy is begun until at least 4 to 6 weeks postoperatively. At that point, passive and active-assist range of motion activities are initiated with a therapist. Active motion is begun at 8 weeks or with the first radiograph that shows evidence of callous formation. Strengthening is instituted in the last phase typically beginning at 12 weeks and beyond.

### ■ CONCLUSION

Intercalary allograft strut with fixed-angle locked plating has been highly successful at our institution. Ultimately, in our experience, this technique is successful, offers predictable union and clinical outcomes, and eliminates the risk of host site morbidity associated with autograft techniques.

## ■ REFERENCES

1. Nayak NK, Schickendantz MS, Regan WD, et al. Operative treatment of nonunion of surgical neck fractures of the humerus. *Clin Orthop*. 1995;313:200–205.
2. Volgas DA, Stannard JP, Alonso JE. Nonunions of the humerus. *Clin Orthop*. 2004;419:46–50.
3. Einarsson F. Fracture of the upper end of the humerus. Discussion based on the follow-up of 302 cases. *Acta Orthop Scand*. 1958;27(suppl 32):1–215.
4. Neer CS II, Rockwood CA. Fractures and dislocations of the shoulder. In: Rockwood CA Jr, Green DD eds. *Fractures*, vol. 1. Philadelphia, PA: J. B. Lippincott, 1975:610.
5. Neer CS II. Displaced proximal humeral fractures. Part I. Classification and evaluation. *J Bone Joint Surg Am*. 1970;52A:1077.
6. Scheck M. Surgical treatment of nonunions of the surgical neck of the humerus. *Clin Orthop*. 1982;167:255–259.
7. Sorensen KH. Pseudoarthrosis of the surgical neck of the humerus. *Acta Orthop Scand*. 1964;34:132–138.
8. Coventry MB, Laurnen EL. Ununited fractures of the middle and upper humerus: special problems in treatment. *Clin Orthop*. 1970;69:192–198.
9. Epps CH Jr, Cotler JM. Complications of treatment of fractures of the humeral shaft. In: Epps CH Jr ed. *Complications in Orthopaedic Surgery*, 2nd ed. Philadelphia, PA: J. B. Lippincott, 1986:277–304.
10. Gristina AG. Management of displaced fractures of the proximal humerus. *Contemp Orthop*. 1987;15:61–93.
11. Leach RE, Premer RF. Nonunion of the surgical neck of the humerus: method of internal fixation. *Minn Med*. 1965;48:318–322.
12. Mayer PJ, Everts CM. Nonunion, delayed union, malunion and avascular necrosis. In: Epps CH Jr ed. *Complications in Orthopaedic Surgery*, 2nd ed. Philadelphia, PA: J. B. Lippincott, 1986:207–230.
13. Muller ME, Thomas RJ. Treatment of nonunion in fractures of long bones. *Clin Orthop*. 1979;138:141–153.
14. Paavolainen P, Bjorkenheim JM, Slati P, et al. Operative treatment of severe proximal humeral fractures. *Acta Orthop Scand*. 1983;54:374–379.
15. Ray RD, Sankaran B, Fetrow KO. Delayed union and nonunion of fractures. *J Bone Joint Surg Am*. 1964;46:627–643.
16. Rooney PJ, Cockshott WP. Pseudoarthrosis following proximal humeral fractures: a possible mechanism. *Skeletal Radiol*. 1986;15:21–24.
17. Wirth MA. Late sequelae of proximal humerus fractures. *Instr Course Lect*. 2003;52:13–16.
18. Antuna SA, Sperling JW, Sanchez-Sotolo, et al. Shoulder arthroplasty for proximal humeral nonunions. *J Shoulder Elbow Surg*. 2002;11:114–121.

19. Healy WL, Jupiter JP, Kristiansen TK, et al. Nonunion of the proximal humerus. A review of 25 cases. *J Orthop Trauma*. 1990;4:424–431.
20. Bosworth DM. Blade plate fixation: technique suitable for fractures of the surgical neck of the humerus and similar lesions. *JAMA*. 1949;141:1111–1113.
21. Duralde XA, Flatow EL, Pollock RG, et al. Operative treatment of nonunions of the surgical neck of the humerus. *J Shoulder Elbow Surg*. 1996;5:169–180.
22. Neer CS II. Displaced proximal humeral fractures. Part II. Treatment of three-part and four-part displacements. *J Bone Joint Surg Am*. 1970;52A:1090.
23. Norris TR, Turner JA, Bovill D. Nonunion of the upper humerus: an analysis of the etiology and treatment in 28 cases. In: Post M, Morrey BF, Hawkins RJ eds. *Surgery of the Shoulder*. St Louis, MO: Mosby, 1990: 63–67.
24. Ring D, McKee M, Perey B, et al. The use of a blade plate and autogenous cancellous bone graft in the treatment of ununited fractures of the proximal humerus. *J Shoulder Elbow Surg*. 2001;10:501–507.
25. Sehr JR, Szabo RM. Semitubular blade plate fixation in the proximal humerus. *J Orthop Trauma*. 1988;2:327–332.
26. Walch G, Badet R, Nove-Josserand L, et al. Nonunions of the surgical neck of the humerus: surgical treatment with an intramedullary bone peg, internal fixation, and cancellous bone grafting. *J Shoulder Elbow Surg*. 1996;5:161–168.
27. Heary RF, Schlenk RP, Sacchieri TA, et al. Persistent iliac crest donor site pain: independent outcome assessment. *Neurosurgery*. March 2002;50(3):510–516. [discussion 516–517].
28. Wright TW. Treatment of humeral diaphyseal nonunions in patients with severely compromised bone. *J South Orthop Assoc*. 1997;6:1–7.